Core Muscle Injuries in Athletes

Alexander E. Poor, MD[1]; Johannes B. Roedl, MD, PhD[2]; Adam C. Zoga, MD[2]; and William C. Meyers, MD[1]

Abstract
Lower abdominal and groin injuries are among the most common causes of pain and lost playing time in sports. Perhaps the most important obstacle in understanding these injuries is the lack of consensus on nomenclature. There have been numerous advances in recent years in the understanding, prevention, diagnosis, and treatment of these injuries. The purpose of this review is to provide a general perspective on the current understanding of these injuries and a summary of recent advances.

Introduction

Lower abdominal and groin injuries are among the most common causes of pain and lost playing time in sports (1). The purpose of this review is to provide a general perspective on the current understanding of these injuries and a summary of recent advances. We are, in many ways, still in the early stages of what is a new field in medicine. There remains controversy and confusion about simply what to call the injuries that cause groin pain in athletes. The variations in nomenclature reinforce different ways of thinking about the pathophysiology, diagnosis, and treatment of these injuries. Similarly, the confusion over what we are talking about complicates the task of tracking epidemiology. Some of the best information we have resulted from researchers tracking the frequency of pain at various locations without asserting the underlying pathophysiology. Despite this confusion, there have been advances in prevention, diagnosis, and treatment.

Terminology

Perhaps the most important obstacle in understanding these injuries is the lack of consensus on nomenclature. One fundamental problem is that we have no anatomic landmarks for the groin. "Groin" is a term that seems familiar but is imprecise. Consider the review in the *British Journal of Sports Medicine* in 2005 (2). It is an excellent meta-analysis of 25 articles from the literature. One conclusion was that "groin" injuries made up 7% of all lower extremity injuries in soccer. If one considers the other injury categories used by the researchers that reasonably may involve the core muscles, specifically "hip" and "upper leg," one could estimate the proportion to be 26%.

There have been many recent attempts to achieve agreement with many new terms appearing in the last few years. The terms "sports hernia" and the more recently proposed "inguinal disruption" both imply that the abdominal wall is in need of reinforcement (3). "Athletic pubalgia," a term proposed as an alternative to "sports hernia," simply describes the presence of pain around the pubic bone in athletes (4). While this term avoids any implicit bias, it is a nonspecific description of the symptom. Another purely descriptive term is *osteitis pubis*. It describes the presence of inflammation at the pubic bone or symphysis and is not always present in athletes with chronic groin pain. The First World Conference on Groin Pain in Athletes brought together an impressive group of leaders in the field. The results of this Doha agreement were published in 2015 and provided four new subcategories of groin pain: adductor-related, inguinal-related, pubic-related, and iliopsoas-related groin pain. They also highlight the contribution of intra-articular hip pathology and other nonmusculoskeletal processes (5). These terms are useful in that they promote more precise descriptions of the anatomic structures involved and reflect that there are many processes that contribute to groin pain in athletes.

Another term that takes into account the many anatomic structures that may be involved in causing groin pain is *core injury* (6). The concept of "the core" was established by exercise and fitness experts and refers to the entire body from the chest to the mid-thigh. This classification system, like the one proposed in the Doha agreement, allows for further subcategorization based on the anatomic structures involved. Specifically, there are four broad categories of core injuries: muscular, hip, back, and everything else.

A *core muscle injury* refers to damage to any skeletal muscle within the area between the chest and mid-thigh. These muscles are symmetrically arranged around the pubic bone and thinking about the anatomy this way helps one understand the pathophysiology of a lot of these injuries. The muscles that originate and/or insert onto the fibrocartilage plate covering the pubic bone play important roles in pelvic stability and constitute the harness that allows the torso to move with the legs. This central stability functionally anchors

[1]Vincera Institute, Philadelphia, PA; and [2]Department of Radiology, Thomas Jefferson University Hospital, Philadelphia, PA

Address for correspondence: Alexander Edward Poor, MD, Vincera Institute, Philadelphia, PA; E-mail: apoor@vincerainstitute.com.

1537-890X/1702/54–58
Current Sports Medicine Reports
Copyright © 2018 by the American College of Sports Medicine

Copyright © 2018 by the American College of Sports Medicine. Unauthorized reproduction of this article is prohibited.

the pelvis so that more distal parts of the body can move efficiently. The rectus abdominis flexes the trunk and forms the anchor for considerable abduction and adduction, as well as internal and external hip rotation. Laterally, the rectus abdominis attaches to the obliques via pure fibrous connections, enveloping complexes of nerves and tiny vascular structures. Three adductors — the pectineus, the adductor longus, and the adductor brevis — insert onto the fibrocartilage of the pubic bone adjacent to the rectus abdominis and play a primary role in core stability. Other muscles, such as the iliopsoas and rectus femoris, can be involved as well. In a review of experience with more than 8000 patients, these muscles were involved in 3% and 4% of cases, respectively (7). Describing the muscular injuries using the actual muscles involved allows patterns to emerge that will hopefully influence prevention and treatment.

Epidemiology and Prevention

The inconsistent nomenclature and diversity of organ systems and processes that can give rise to groin pain in athletes makes tracking the incidence particularly difficult. By using categories based on the locations of pain, we do know that injuries of the upper leg, groin, and hip are among the most common injuries in sport (2,8,9). A recent weekly survey of soccer players found the weekly prevalence of "groin problems" to be 29% (10). Previous adductor or groin injury is the most consistently-identified risk factor for subsequent injury (11,12). We have found that distal scarring from a muscle belly injury can increase the forces applied at the pubic bone attachment and can accelerate a central injury. In our practice, 16% of patients have symptomatic intra-articular hip pathology in addition to muscular injury. Hip arthroscopists have described a similar overlap between femoroacetabular impingement and muscular injuries (13,14). Similarly, decreased hip range of motion has been identified as a risk factor for the development of chronic groin pain (12).

As we gain a better understanding of the risk factors for core muscle injuries, we must revisit the way we train with an eye towards injury prevention. The FIFA 11+ Injury Prevention Program is an excellent example of a program that incorporates core stabilization and has proven to be effective in preventing injury (15,16).

Diagnosis and Imaging

The difficulties in choosing which diagnostic tests to order after completing a detailed history and physical exam result from the confusing terminology. One must consider the muscles involved; there is complex anatomy surrounding the pubic bone, all of which has the potential to contribute to an injury. Ultrasound can be useful in detailed visualization of structures but its use can be misleading in identifying hernias. The proximity of the inguinal canal to the caudal rectus abdominis attachment contributes to some of the confusion. Normal inguinal fat occurs in the spermatic cords or round ligament. Likewise, retroperitoneal fat extending into the inguinal canal is commonly observed on magnetic resonance imaging (MRI), but should not typically be considered a true hernia. If a true hernia is suspected, prone imaging and dynamic sequences with either MRI or ultrasound can be used. As previously stated, laxity of the internal inguinal ring or floor of the inguinal canal is often a byproduct, or secondary sign, of a more central injury involving the muscular attachments to the pubic bone. Because ultrasound is relatively inexpensive and widely available, it is often an appropriate next step. The presence of edema around the pubic bone or along the surrounding musculature, or signs of atrophy or laxity of the abdominal wall should prompt one to get an MRI with the "athletic pubalgia" protocol to better define the muscles involved (17,18).

Plain Radiographs

Because of the frequency of concomitant hip and core muscle injuries, we have made it a part of our routine practice to get plain films of the pelvis and hip. Documenting the presence of femoroacetabular impingement and hip dysplasia is useful in understanding and treating the acute injury, aids in the workup of future injuries or pain, and informs how an athlete should train with respect to injury prevention (19). Plain x-rays also are important in the detection of heterotopic ossification which we see in the presence of old avulsion injuries and, as will be discussed later in this article, after platelet-rich plasma (PRP) injections.

In our practice, we routinely use MRI in working up groin pain. Many patterns of injury have emerged, and we have, along with our radiology colleagues, established a nomenclature system for the MRI findings associated with core muscle injuries. The importance of defining all of the structures involved in an injury cannot be overstated. A poor-quality MRI can be as misleading as an ultrasound. For example, MRI of core muscle injuries without appropriate dedicated images of the pubic bone will often show a diffuse haziness around the pubic bone. This is, reasonably, interpreted as a pubic bone stress fracture and the patient is made non-weight-bearing for months. Rest will almost certainly alleviate the symptoms, but if the injury is related to a muscular detachment, the pain will return upon resuming athletic activities.

MRI Findings in Core Muscle Injuries

The primary finding associated core muscle injuries have been previously summarized (20). We place primary importance on the presence of fluid between the pubic bone and the overlying fibrocartilage plate. Defining the precise location of this fluid is important and we make use of an as-of-yet unpublished classification system (Figs. 1–5). A *midline* plate detachment refers to a separation of the fibrocartilage cover of the pubic bone overlying the width of the pubic symphysis. In our anecdotal experience, these tend to be symmetrical and distinct from the *lateral* plate detachments, which involve the fibrocartilage to the left or right of the symphysis. *Posterior extension* of the plate detachment extends along the pubic ramus and, in skeletally immature patients, this can take place along the growth plate (*i.e.,* subphyseal). This has been referred to as a "secondary cleft." *Chronic* plate detachments occur in long-standing injuries where spicules of granulation tissue fill in portions of the gap between the fibrocartilage plate and pubic bone. *Degenerative* plate detachments have a similar appearance but the edges of the fibrocartilage develop a lytic appearance, and we think these occur with repetitive trauma. Peripubic and bone marrow edema occurs in the presence of injury and is an important marker for plate detachments.

Copyright © 2018 by the American College of Sports Medicine. Unauthorized reproduction of this article is prohibited.

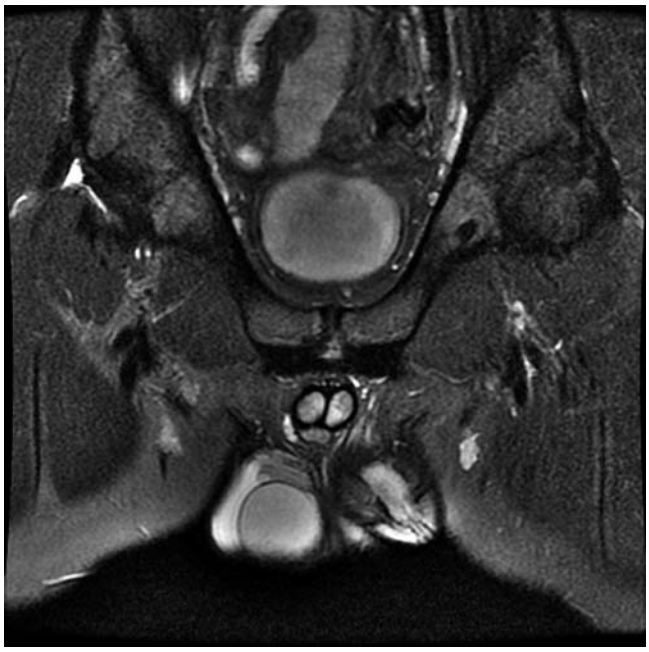

Figure 1: Examples of core muscle injury features on MRI. Fluid is white in these axial-oblique T2-weighted fat-saturated MR images. These demonstrate *midline* (1), *lateral* (2), *chronic* (3), *degenerative* (4) plate detachments, and *posterior extension* along the pubic rami (5). Note the pubic bone edema accompanying the plate injuries.

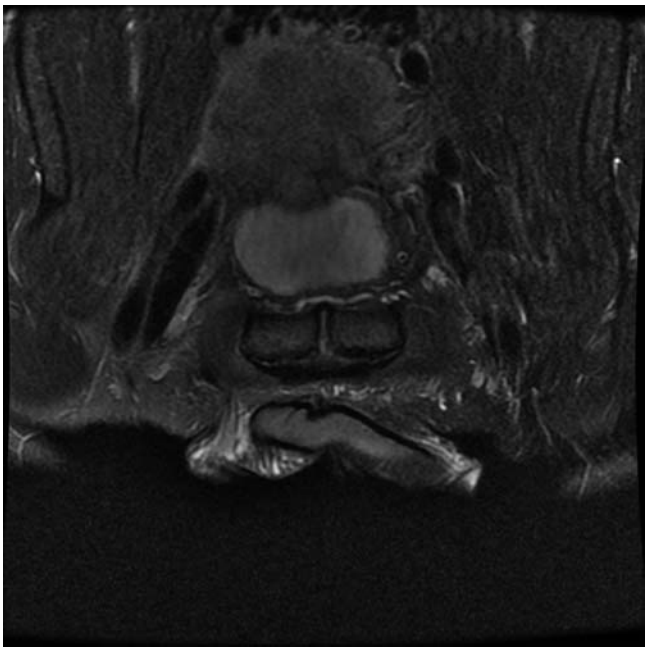

Figure 3: Chronic plate detachment.

Nonoperative Treatment

For certain peripheral injuries, nonoperative management is a first-line treatment. In many cases, it is also required due to special considerations in athletes. These include the timing within a season, concerns about coaching/front office decisions, and the influence of contract negotiations, in addition to the clinical factors. These factors must be considered in deciding when to use aggressive temporizing procedures versus permanent solutions. In general, the first treatment of groin pain involves rest, ice, analgesics, anti-inflammatories, and depending on the resources available, manual therapy, ultrasound, infrared, and so on. Success has been demonstrated in treating these injuries nonoperatively but comparison with surgical outcomes is difficult (11). Many practitioners prescribe physical therapy as a first-line treatment for core muscle injuries, and there is controversy in the literature about the relative efficacy of physical therapy versus surgery. There are many published studies that demonstrate return to play following dedicated exercise programs designed to improve core muscle strength and proprioception (21–23). Classically, these

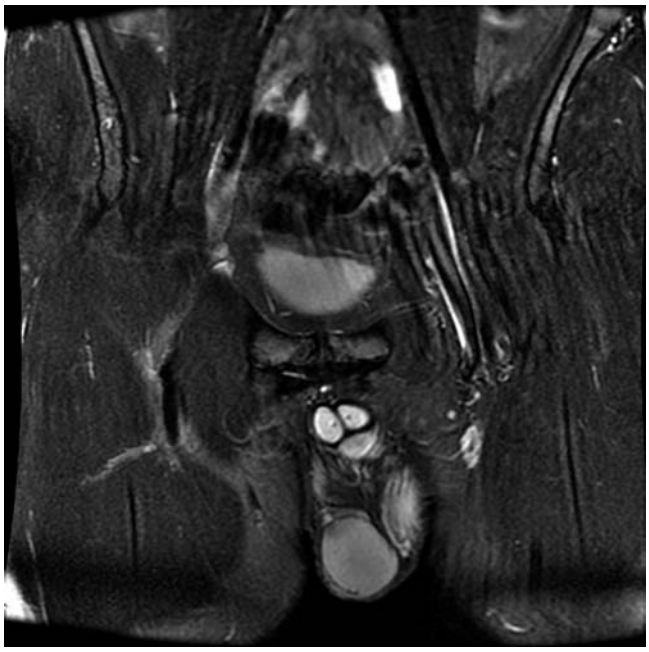

Figure 2: Lateral plate detachment.

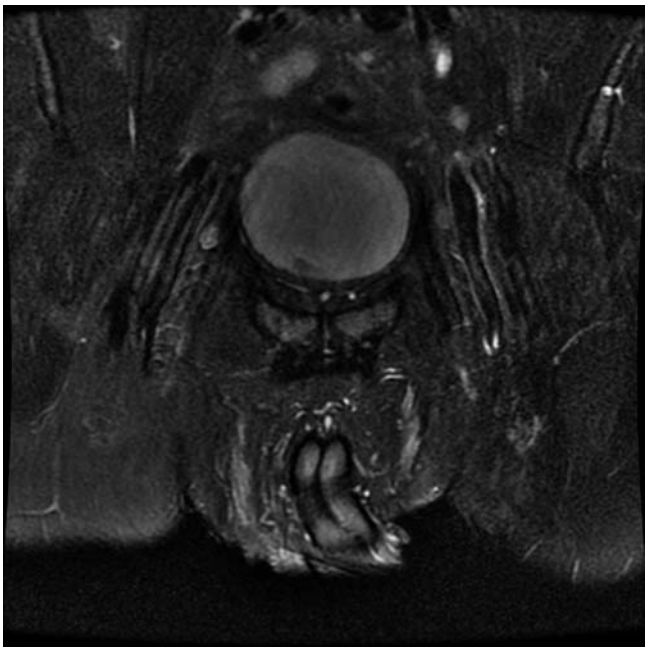

Figure 4: Degenerative plate detachment.

Copyright © 2018 by the American College of Sports Medicine. Unauthorized reproduction of this article is prohibited.

Figure 5: Posterior extension.

injuries improve with rest but the pain returns upon resuming activities. This period of rest, however, is not a required component of the diagnostic workup, and someone with signs and symptoms of a core muscle injury need not wait to start physical therapy or proceed with definitive repair.

Regarding the nonoperative approach to temporize a central core muscle injury, we prefer corticosteroid injections directly into the areas of injury and inflammation. Overall, in our experience, about 80% of players with core injuries returned to high-level play for the duration of the season and delaying definitive repair did not adversely affect postoperative outcomes. Other factors, however, such as the timing of the injection and the presence of clinically significant hip pathology are likely significant factors in determining whether this approach will be successful. To our knowledge, there are no outcome studies for the use of corticosteroid injections to treat core muscle injuries, but they are widely used and the techniques have been well described (24). Pubic symphyseal or cleft injections also have been described and are widely used (25). We do not advocate the use of this technique as we have determined that these injections are effective only if the plate detachment is confluent with the pubic cleft. We are not aware of any studies comparing these techniques.

Platelet-rich plasma has become a popular treatment for a variety of sports-related injuries including chronic groin pain. There are few published studies describing its use (26–28). In our practice, we have seen an increased incidence of prior PRP injections among the patient population and with it an increase in heterotopic bone formation at or near the area of injury within the adductor muscles. Before the introduction of PRP about 5 years ago, similar ossification occurred in the presence of long-standing avulsions or previous surgical adductor division. There is certainly a selection bias when studying our patient population in that we tend not to see athletes with success from prior treatments. A prospective study looking at heterotopic ossification as a potential long-term complication from PRP injections would certainly shed light on the true incidence of this phenomenon. We will be publishing our retrospective results and hope to promote caution and stimulate discussion about the use of PRP in the musculature around the pubic bone.

Operative Treatment

Most injuries that cause chronic lower abdominal and groin pain in athletes are not simply occult hernias or impinged nerves. They usually involve multiple muscles, and there is significant interaction with the hip joints. Treatment should be directed towards restoring normal anatomy across the pubic bone. This often refers to the rectus abdominis and adductors and restoring the balance between the forces applied by these opposing muscle groups. That is not to say that these processes do not occur, but the presence of an indirect hernia sac does not rule out a muscular injury. Disrupting the pubic bone attachment of the abdominal wall musculature can certainly result in laxity of the floor of the inguinal canal and internal inguinal ring. There have been numerous publications demonstrating success with treating this laxity as the primary culprit (29). Mesh fibrosis seems to help stabilize the rectus abdominis at the pubic bone but this has not been demonstrated. In our practice, we regularly see patients with mesh-related inguinodynia and persistent pain from unresolved muscular injuries. The use of mesh in treatment of these injuries is wide-spread and is recommended by many leaders in the field (3,30).

Some advocate division of the adductor pubic bone attachments to decrease the forces on the pubic bone, with (31) or without (32) placement of inguinal mesh. We do not recommend this approach because of the importance of balancing the forces applied at the pubic bone by the rectus abdominis and adductors. Additionally, dividing the pubic bone attachments of the adductors may leave athletes with a functional weakness.

It is worth emphasizing that many core injuries involve elements other than the rectus abdominis and adductors. Careful consideration of all structures involved leads to appropriate management and this often means coordination with hip arthroscopists. As previously stated, 16% of patients in our practice have both a muscular and hip injury. In addition, pain related to psoas impingement can be treated by lengthening procedures at the level of the femoral attachment and/or at the level of the hip joint (33). We have treated more than 200 patients with combined hip arthroscopy and core muscle repairs with 88% of athletes returning to play by 6 months postoperatively.

Despite the variations in surgical technique, most publications report success with treating these injuries surgically (25,34–36). There is less controversy regarding the importance of physical therapy in the postoperative period and a progression to return to play. Surgical treatment of core muscle injuries is one part of what should be a comprehensive and multidisciplinary collaboration between athletic trainers, physical therapists, sports medicine physicians, radiologists, and orthopedic surgeons.

Conclusions

There have been exciting advances in the understanding and treatment of groin pain in athletes. We have clearly established that these injuries represent an important and complex challenge

Copyright © 2018 by the American College of Sports Medicine. Unauthorized reproduction of this article is prohibited.

for sports medicine practitioners and a field that is in rapid evolution. There is much to be gained by eschewing the imprecise nomenclature and ways of thinking that go along with them. Instead, using precise terminology to describe the structures involved allows for more precise analysis and comparison of various treatment modalities.

The authors declare no conflict of interest and do not have any financial disclosures.

References

1. Whittaker JL, Small C, Maffey L, Emery CA. Risk factors for groin injury in sport: an updated systematic review. *Br. J. Sports Med.* 2015; 49:803–9.
2. Wong P, Hong Y. Soccer injury in the lower extremities. *Br. J. Sports Med.* 2005; 39:473–82.
3. Sheen AJ, Stephenson BM, Lloyd DM, *et al*. Treatment of the sportsman's groin: British Hernia Society's 2014 position statement based on the Manchester Consensus Conference. *Br. J. Sports Med.* 2014; 48:1079–87.
4. Taylor DC, Meyers WC, Moylan JA, *et al*. Abdominal musculature abnormalities as a cause of groin pain in athletes. Inguinal hernias and pubalgia. *Am. J. Sports Med.* 1991; 19:239–42.
5. Weir A, Brukner P, Delahunt E, *et al*. Doha agreement meeting on terminology and definitions in groin pain in athletes. *Br. J. Sports Med.* 2015; 49:768–74.
6. Meyers WC, Havens BK, Horner GJ. Core muscle injury (a better name than "athletic pubalgia" or "sports hernia"). *Curr. Orthop. Pract.* 2014; 25:321–6.
7. Meyers WC, McKechnie A, Philippon MJ, *et al*. Experience with "sports hernia" spanning two decades. *Ann. Surg.* 2008; 248:656–65.
8. Brophy RH, Wright RW, Powell JW, *et al*. Injuries to kickers in American football: the National Football League experience. *Am. J. Sports Med.* 2010; 38:1166–73.
9. Engebretsen A, Myklebust G, Holme I, *et al*. Intrinsic risk factors for groin injuries among male soccer players: a prospective cohort study. *Am. J. Sports Med.* 2010; 38:2051–7.
10. Harøy J, Clarsen B, Thorborg K, *et al*. Groin problems in male soccer players are more common than previously reported. *Am. J. Sports Med.* 2017; 45: 1304–8.
11. Garvey JFW, Hazard H. Sports hernia or groin disruption injury? Chronic athletic groin pain: a retrospective study of 100 patients with long-term follow-up. *Hernia*. 2014; 18:815–23.
12. Hölmich P, Thorberg K, Dehlendorff C, *et al*. Incidence and clinical presentation of groin injuries in sub-elite male soccer. *Br. J. Sports Med.* 2014; 48: 1245–50.
13. Hammoud S, Bedi A, Magennis E, *et al*. High incidence of athletic pubalgia symptoms in professional athletes with symptomatic femoroacetabular impingement. *Arthroscopy.* 2012; 28:1388–95.
14. Rankin AT, Bleakley CM, Cullen M. Hip joint pathology as a leading cause of groin pain in the sporting population: a 6-year review of 894 cases. *Am. J. Sports Med.* 2015; 43:1698–703.
15. Bizzini M, Dvorak J. FIFA 11+: an effective programme to prevent football injuries in various player groups worldwide — a narrative review. *Br. J. Sports Med.* 2015; 49:577–9.
16. Jones NS. Update: soccer injury and prevention, concussion, and chronic groin pain. *Curr. Sports Med. Rep.* 2014; 13:319–25.
17. Omar IM, Zoga AC, Kavanagh EC, *et al*. Athletic pubalgia and "sports hernia": optimal MR imaging technique and findings. *Radiographics*. 2008; 28: 1415–38.
18. Zoga AC, Kavanagh EC, Omar IM, *et al*. Athletic pubalgia and the "sports hernia": MR imaging findings. *Radiology.* 2008; 247:797–807.
19. Stull JD, Philippon MJ, LaPrade RF. "At-risk" positioning and hip biomechanics of the Peewee ice hockey sprint start. *Am. J. Sports Med.* 2011; (Suppl 39): 29S–35.
20. Palisch A, Zoga AC, Meyers WC. Imaging of athletic pubalgia and core muscle injuries: clinical and therapeutic correlations. *Clin. Sports Med.* 2013; 32:427–47.
21. Becker LC, Kohlrieser DA. Conservative management of sports hernia in a professional golfer: a case report. *Int. J. Sports Phys. Ther.* 2014; 9:851–60.
22. Hölmich P, Uhrskou P, Ulnits L, *et al*. Effectiveness of active physical training as treatment for long-standing adductor-related groin pain in athletes: randomised trial. *Lancet.* 1999; 353:439–43.
23. King E, Ward J, Small L, *et al*. Athletic groin pain: a systematic review and meta-analysis of surgical versus physical therapy rehabilitation outcomes. *Br. J. Sports Med.* 2015; 49:1447–51.
24. McCarthy E, Hegazi TM, Zoga AC, *et al*. Ultrasound-guided interventions for core and hip injuries in athletes. *Radiol. Clin. North Am.* 2016; 54:875–92.
25. Lynch TS, Bedi A, Larson CM. Athletic hip injuries. *J. Am. Acad. Orthop. Surg.* 2017; 25:269–79.
26. Dallaudière B, Pesquer L, Meyer P, *et al*. Intratendinous injection of platelet-rich plasma under US guidance to treat tendinopathy: a long-term pilot study. *J. Vasc. Interv. Radiol.* 2014; 25:717–23.
27. Kraeutler MJ, Garabekyan T, Mei-Dan O. The use of platelet-rich plasma to augment conservative and surgical treatment of hip and pelvic disorders. *Muscles Ligaments Tendons J.* 2016; 6:410–9.
28. St-Onge E, MacIntyre IG, Galea AM. Multidisciplinary approach to non-surgical management of inguinal disruption in a professional hockey player treated with platelet-rich plasma, manual therapy, and exercise: a case report. *J. Can Chiropr. Assoc.* 2015; 59:390–7.
29. Kopelman D, Kaplan U, Hatoum OA, *et al*. The management of sportsman's groin hernia in professional and amateur soccer players: a revised concept. *Hernia*. 2016; 20:69–75.
30. Paajanen H, Brinck T, Hermunen H, *et al*. Laparoscopic surgery for chronic groin pain in athletes is more effective than non-operative treatment: a randomized clinical trial with magnetic resonance imaging of 60 patients with sportsman's hernia (athletic pubalgia). *Surgery.* 2011; 150:99–107.
31. Rossidis G, Perry A, Abbas H, *et al*. Laparoscopic hernia repair with adductor tenotomy for athletic pubalgia: an established procedure for an obscure entity. *Surg. Endosc.* 2015; 29:381–6.
32. Harr JN, Brody F. Sports hernia repair with adductor tenotomy. *Hernia*. 2017; 21:139–47.
33. Philippon MJ, Devitt BM, Campbell KJ, *et al*. Anatomic variance of the iliopsoas tendon. *Am. J. Sports Med.* 2014; 42:807–11.
34. Choi HR, Elattar O, Dills VD, *et al*. Return to play after sports hernia surgery. *Clin. Sports Med.* 2016; 35:621–36.
35. Larson CM. Sports hernia/athletic pubalgia: evaluation and management. *Sports Health*. 2014; 6:139–44.
36. Mai HT, Alvarez AP, Freshman RD, *et al*. The NFL orthopaedic surgery outcomes database (NO-SOD): the effect of common orthopaedic procedures on football careers. *Am. J. Sports Med.* 2016; 44:2255–62.

Copyright © 2018 by the American College of Sports Medicine. Unauthorized reproduction of this article is prohibited.